

Anti-RAGE (Receptor Advanced Glycation End products) Antibody Improves Diabetic Retinopathy in Rats via Hypoglycemic and Anti-inflammatory Mechanism

Ramzi Amin*¹, Tiara Bunga Indiarsih², Prima Maya Sari¹, Petty Purwanita¹

Abstract

Background: Receptor advanced glycation end products (RAGE) activation plays an essential role in diabetic retinopathy (DR) progression. This study was aimed to explore the role of anti-RAGE antibodies (RAGE antagonists) in inhibiting DR progression through their hypoglycemic and anti-inflammatory mechanism in diabetic retinopathy induced rats.

Methods: A total of 30 male Wistar rats were randomly divided into five group. The group was consisted of normal control group, DR group without treatment, DR group with anti-RAGE 1 ng/kg BW, 10 ng/kg BW, and 100 ng/kg BW. To assess the diabetic retinopathy, fundus photographs were taken every week using a camera with 16x magnification placed in front of the rat's eyes. Blood glucose was checked by the glucose oxidase-peroxidase method. Retinal TNF- α levels and VEGF were examined using an enzyme-linked immunosorbent assay (ELISA) kit.

Results: The finding of this study showed that anti-RAGE treatment at dose of 10 and 100 ng/kg BW, HbA1c levels were significantly higher ($p < 0.05$) compared to the normal control group but significantly lower ($p < 0.05$) than in the diabetes group. The mean blood vessel diameter in the DR+anti-RAGE 10 and 100 ng/kg BW groups was significantly lower than in the diabetic retinopathy group ($p < 0.05$). The administration of anti-RAGE 10 and 100 ng/kg BW showed the ability to significantly reduce VEGF levels compared to the DR group ($p < 0.05$).

Conclusions: This study revealed at doses of 10 and 100 ng/kg BW, anti-RAGE antibodies improved diabetic retinopathy in Wistar rats through hypoglycemic effects and anti-inflammatory mechanisms.

Keywords: Anti-RAGE (Receptor Advanced Glycation End products), Diabetic Retinopathy, Glycated Hemoglobin A, Hypoglycemic Agents, Peroxidases, Vascular Endothelial Growth Factor A.

Introduction

Diabetic retinopathy is one of diabetes mellitus complication in retinal microvascular (1). It is the most common causes of blindness worldwide (1). Diabetes mellitus causes increased oxidative stress and plays an essential role in the pathogenesis of complications of diabetes mellitus (2,3). Oxidative stress produces a series of free radicals, which trigger the upregulation of

activation of a cascade of pro-inflammatory mediators such as vascular endothelial growth factor (VEGF) and tumor necrosis factor (TNF- α) (4). These mediators play a role in triggering the upregulation of adhesion molecules of endothelial cells and leucocytes (4). Furthermore, leukostasis causes occlusion, tissue ischemia, edema, loss of neuronal functions, and neuronal cell death (5). Early

1: Department of Ophthalmology, Faculty of Medicine Universitas Sriwijaya/ Dr Moh Hoesin General Hospital, Palembang, Indonesia.

2: Specialized Residency Training, Faculty of Medicine Universitas Sriwijaya/Dr Moh Hoesin General Hospital, Palembang, Indonesia.

*Corresponding author: Ramzi Amin; Tel: +62 81949581088; Email: ramziamin20@gmail.com.

Received: 12 Apr, 2022; Accepted: 21 Apr, 2022

histopathological changes in diabetic retinopathy are found in selective loss of pericytes, capillary basement membrane thickening, hyperpermeability, and the formation of microaneurysms. Microvascular occlusion, neovascularization, and neurodegeneration follow these structural and functional changes (6).

Receptor Advanced Glycation End products (RAGE) is known to accumulate gradually in diabetes mellitus conditions due to impaired blood sugar regulation and is also one of the pattern recognition receptors (7). The RAGE signaling causes the activation of inflammatory mediators and actively causes the progression of chronic inflammation such as arteriosclerosis, Alzheimer's disease, and diabetic retinopathy (7,8). It consists of two forms, a transmembrane signaling receptor and an in-soluble form known as sRAGE. Soluble RAGE is found in many tissues, including retinal tissue. Activation of RAGE will cause upregulation of oxidative stress and inflammatory activity, where these conditions play an essential role in the progression of complications of diabetes mellitus, including diabetic retinopathy (9). This study is one of the initial studies aimed at exploring the role of anti-RAGE antibodies, which act as RAGE antagonists, in inhibiting the progression of diabetic retinopathy through their hypoglycemic and anti-inflammatory effects *in vivo* in the rat's model of diabetic retinopathy.

Materials and Methods

Animals

Healthy male Wistar strain rats weighing between 220 and 250 g were procured from Eureka Laboratory and Experimental Animal Breeding Co., Ltd (Palembang, Indonesia) and maintained in polypropylene cages at the ambient temperature of 22±1 °C and relative humidity of 50-60% with a 12 h light/dark cycle in the registered animal house (889/ELR/2021) at Eureka Research Laboratory, Palembang, Indonesia. Throughout the treatment, the animals were

fed with standard pellet diet (Comfeed, Indonesia) and water ad libitum. Age matching was done in the control group.

Experimental procedure

Diabetes mellitus in rats was induced with streptozotocin (STZ, 45 mg/kg BW) (10). Blood glucose levels were assessed at the beginning of the induction of diabetes mellitus and 24 hours after STZ/vehicle injection in all groups. Rats showing blood glucose levels of more than 200 mg/dL were considered diabetes mellitus. After having diabetes mellitus for 12 weeks, the rats were examined for fundus photography to obtain a funduscopy image of the rat retina to determine the occurrence of diabetic retinopathy. Diabetic rats were divided into four treatment groups and one control group (without the induction of diabetes mellitus), where each group consisted of six rats. Group 1 received phosphate-buffered saline (PBS) (Sigma Aldrich, Singapore) one mL intravitreal single dose, Groups 2, 3 and 4 each received Anti-RAGE (Abcam, Singapore) 1, 10, and 100 ng/kg BW intravitreal single dose, group 5 is a normal control. The rats were euthanized after 30 days of treatment by administering a pentobarbital overdose. The retina was isolated and frozen in liquid nitrogen for further biochemical examination.

Preparation of intravitreal suspension

Anti-RAGE antibodies were obtained from Abcam. The glass pipettes were prepared using a pipettes puller, then it was connected to a 1 ml syringe. The connection between was sealed with parafilm. Two ml of the solution was withdrawn into the tip of pipettes. The rats anesthetized by intraperitoneal injection of ketamine (80 mg/kg) and xylazine (8 mg/kg) (volume ratio at 2:1). One drop of 0.5% Alcaine® (proparacaine hydrochloride ophthalmic solution) were applied to the eyes as topical anesthetics before intravitreal injection. The rats were positioned and exposed the superior nasal region of the eye. A 30-gauge needle was used to puncture the superior nasal sclera at the level of the par

plana. This procedure was done without touching the ocular muscle and vessels.

The eyeballs were given mild pressure to get rid a small amount of vitreous through the puncture hole from posterior chamber. Then, the tip of glass pipette was inserted through the puncture hole at a 45° angle via sclera into the vitreous body. Two ml of the solution was injected into the posterior chamber, then gently the needle was pulled. After intravitreal injection, Tobrex® (tobramycin) ointment was applied on the rat eye to prevent infection.

Fundus photography and estimation of retinal vessel diameter

Tropicamide (1%) was applied to dilate the pupil. Fundus photographs were taken every week using a Nikon camera (Jakarta, Indonesia) mounted on a slit lamp with 16x magnification plus a 90D lens placed in front of the rat's eyes. Moisol® eye drops (0.7% hydroxy propyl methyl cellulose) were administered periodically to avoid drying of the cornea. In estimating retinal vessel diameter, we used the method described in the study by Vucetic et al (11). The diameters of the three most prominent veins were estimated at three locations in the widest section at the same distance from the center. Prior to diameter estimation, retinal photographs of all groups were randomized, and three independent observers performed the estimation. The mean of three estimates was taken as the final retinal vessel diameter.

Glycemic parameters

Blood glucose was checked by the glucose oxidase-peroxidase method using a commercially available kit by piercing the distal end of the mouse tail with the Accu-Chek Softclix Lancing Device on an Active Glucose Test Strip (Roche Diagnostics, Chennai, India). Glycosylated hemoglobin (HbA1c) was estimated using an ion exchange resin kit (Biosystems S.A., Barcelona, Spain).

Inflammatory Cytokine Parameters

According to the manufacturer's instructions, retinal TNF- α levels were examined using a

commercial enzyme-linked immunosorbent assay (ELISA) kit from Diaclone (Diaclone, Besançon, France). According to the manufacturer's instructions, rat retinal VEGF was examined using a commercial ELISA Kit from Ray Biotech (Ray Biotech Inc., Georgia, USA). Estimates were made in 100 μ L retinal homogenate. All estimates are done in duplicate examination.

Statistical analysis

Data were analyzed using SPSS 25.0 (SPSS, Inc., Armonk, NY, United States). All data are presented as mean and standard deviation. Each group was compared with a one-way ANOVA followed by a Tukey post-hoc. If the data distribution is not normal or homogeneous, then the comparison between several groups is analyzed using the Kruskal-Wallis's test, and the differences between the two groups are analyzed using the Mann-Whitney test. Figures were generated using Adobe Photoshop (Adobe Software, San Diego, CA, United States).

Ethical approval

All experiments in this study complied with the bioethical research established by the Institutional Animal Care and Use Committee, Faculty of Medicine of Universitas Sriwijaya (No. 075-2021); and its methodology conforms to the published guide "Principle of laboratory animal care" (12).

Results

Fundus photography

Funduscopic examination showed some changes in the diameter of the blood vessels. The mean retinal blood vessel diameter in the normal and diabetic retinopathy groups were 51.9 \pm 4.7 and 60.2 \pm 4.5 pixels, respectively. Meanwhile, the mean retinal blood vessels in the DR+anti RAGE 1, 10, and 100 ng/kg BW groups were 58.5 \pm 3.4, respectively; 55.8 \pm 3.9; 52.2 \pm 3.8; pixels. The mean blood vessel diameter in the DR+anti-RAGE 10 and 100 ng/kg BW groups was significantly lower than in the diabetic retinopathy group ($p < 0.05$).

Glycemic parameters

Blood glucose levels in the diabetic group were significantly higher than in normal rats ($p < 0.05$) at the end of the treatment period. In rats given anti-RAGE 10 and 100 ng/kg BW, blood glucose levels were significantly lower than in the diabetic group ($p < 0.05$) but still higher than

normal ($p < 0.05$). Similarly, the HbA1c level in the diabetic group was significantly higher than in the normal rats ($p < 0.05$). In rats given anti-RAGE 10 and 100 ng/kg BW, HbA1c levels were significantly higher ($p < 0.05$) compared to the normal control group but significantly lower ($p < 0.05$) than in the diabetes group (Table 1).

Table 1. Effect anti RAGE on glycemic parameters after treatment.

	Body weight (grams) \pm SD	Blood glucose (mg/dL) \pm SD	% HbA1c \pm SD
Normal	298.6 \pm 26.5	98.8 \pm 2.3	4.6 \pm 0.5
Diabetic retinopathy (DR)	278.9 \pm 23.5	598.7 \pm 37.3	8.3 \pm 0.6
DR + Anti RAGE 1 ng/kgBW	279.2 \pm 25.8 ^b	576.9 \pm 34.9 ^b	7.9 \pm 0.7 ^b
DR + Anti RAGE 10 ng/kgBW	283.8 \pm 27.6 ^{ab}	378.8 \pm 21.5 ^{ab}	6.8 \pm 0.5 ^{ab}
DR + Anti RAGE 100 ng/kgBW	290.8 \pm 27.3 ^{ab}	305.6 \pm 21.8 ^{ab}	5.6 \pm 0.7 ^{ab}

^a $p < 0.05$ vs diabetic retinopathy group; ^b $p < 0.05$ vs normal group; SD: standard deviation.

Inflammatory parameters

The DR+Anti RAGE 10 and 100 ng/kg BW groups showed the ability to significantly reduce TNF alpha levels compared to the DR group

($p < 0.05$). In line with this, the administration of anti-RAGE 10 and 100 ng/kg BW showed the ability to significantly reduce VEGF levels compared to the DR group ($p < 0.05$) (Fig. 1)

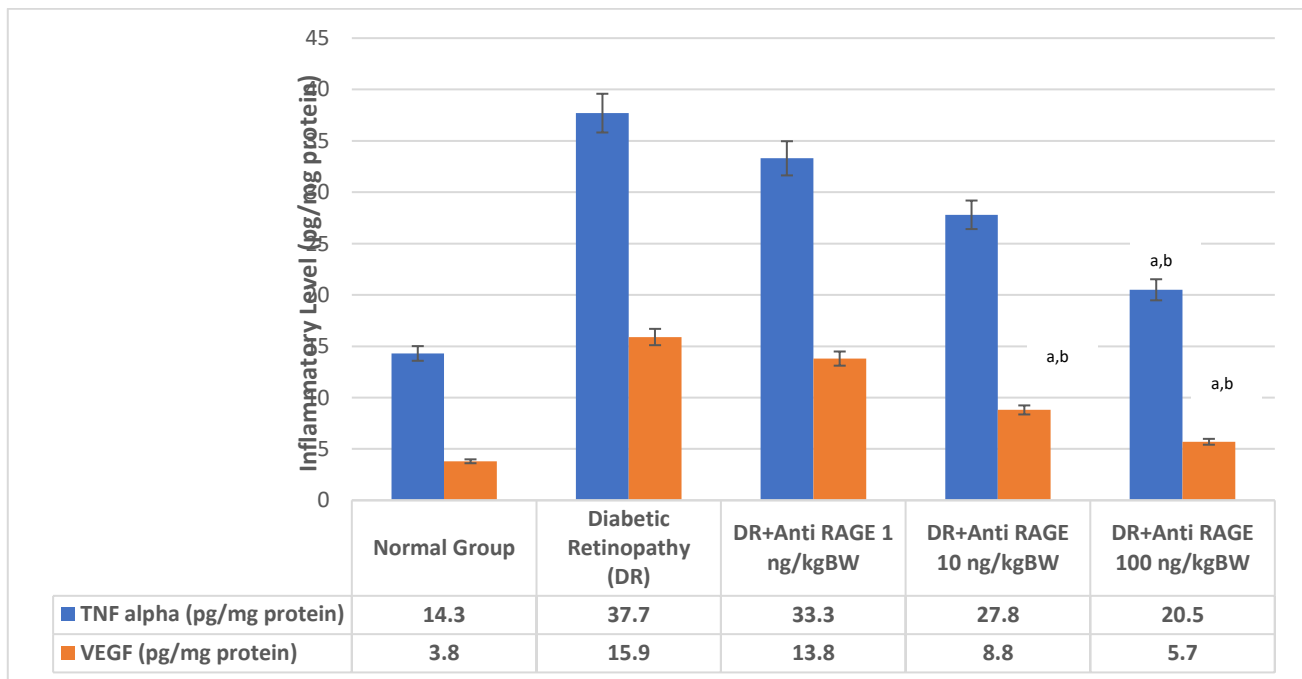


Fig. 1. Inflammatory levels of TNF- α (blue) and VEGF (orange) in rat retinal tissue after treatment. ^a $p < 0.05$ vs diabetic retinopathy group; ^b $p < 0.05$ vs normal group.

Discussion

Various studies have shown that tight control of hyperglycemia over a while prevents the progression of diabetic retinopathy. In most studies, glycosylated hemoglobin (HbA1c) was used to estimate glycemic control (13-15). Studies show a sustained association between the risk of microvascular complications and glycemia, so that for every percentage point decrease in HbA1c (e.g., 9%–8%), there is a 35% reduction in the risk of microvascular complications (15). Treatment with anti-RAGE in this study significantly reduced blood glucose levels compared to untreated diabetic rats (table 1). HbA1c levels in diabetic rats that received anti-RAGE treatment in this study showed reasonable glycemic control.

Various studies have shown that measuring retinal blood vessel diameter can provide prognostic information regarding the risk of microvascular complications of diabetes, including retinopathy (11,16). Previous studies have shown that a wider retinal arteriolar diameter is associated with the incidence and development of diabetic retinopathy (17,18). This study has observed significantly greater dilation of retinal blood vessels in diabetic rats than in normal rats. Administration of anti-RAGE provided a better reduction in retinal blood vessel diameter than the untreated group.

TNF- α , a proinflammatory cytokine, has been implicated in the pathogenesis of diabetic retinopathy, and susceptibility to diabetic retinopathy has been associated with TNF- α gene polymorphisms (19). TNF- α induces endothelial expression of adhesion molecules by activating nuclear factor- κ B (NF- κ B) (20). In addition to upregulation of adhesion molecules,

NF- κ B also increases the expression of other inflammatory mediators, including the enzyme cyclooxygenase-2 (COX-2). Glycosylation products can also activate COX-2. This study showed that TNF- α levels in the retinas of diabetic rats were increased compared to normal rats (Fig. 1). Similarly, another study also showed that retinal TNF- α levels were significantly greater in diabetic rats (21). This study showed that anti-RAGE administration could reduce TNF- α levels in diabetic retinopathy rats.

VEGF is a proinflammatory molecule that plays an essential role in neovascularization and increased vascular permeability, which causes retinal vascular damage (22,23). Various studies show that VEGF is increased in diabetic retinopathy conditions (23,24). This study also showed increased VEGF levels in rats with diabetic retinopathy. Furthermore, inhibition of VEGF activity prevents the development of vascular damage as in diabetic retinopathy. This study demonstrated the potential of anti-RAGE in reducing VEGF levels in rats with diabetic retinopathy.

At doses of 10 and 100 mg/kg BW, anti-RAGE antibodies improved diabetic retinopathy in Wistar male rats through hypoglycemic effects and anti-inflammatory mechanisms.

Acknowledgements

The authors would express their sincere gratitude to Eureka Laboratory Research Palembang for their assistance in this research.

The authors declare that there is no conflict of interest.

References

1. Lee R, Wong TY, Sabanayagam C. Epidemiology of diabetic retinopathy, diabetic macular edema and related vision loss. *Eye Vis (London)*. 2015;2:17.
2. Glovaci D, Fan W, Wong ND. Epidemiology of diabetes mellitus and cardiovascular disease. *Curr Cardiol Rep*. 2019;21(4):21.
3. Endris T, Worede A, Asmelash D. Prevalence of diabetes mellitus, prediabetes and its associated factors in Dessie Town, Northeast Ethiopia: A community-based study. *Diabetes Metab Syndr Obes*. 2019;12:2799-2809.
4. Fischer R, Maier O. Interrelation of oxidative stress and inflammation in neurodegenerative

- disease: Role of TNF. *Oxid Med Cell Longev*. 2015;2015:610813.
5. Rüksam A, Parikh S, Fort PE. Role of inflammation in diabetic retinopathy. *Int J Mol Sci*. 2018;19(4):942.
 6. Zhang W, Chen S, Liu ML. Pathogenic roles of microvesicles in diabetic retinopathy. *Acta Pharmacol Sin*. 2018;39(1):1–11.
 7. Amin R, Ansyori AK, Erna R, Fauzi L. Anti-receptor advanced glycation end products decreases inflammatory pathways in retinopathy diabetics: *in vivo* study. *Open Access Macedonian Journal of Medical Sciences*. 2020;8A:414-417.
 8. Snelson M, Lucut E, Coughlan MT. The role of AGE-RAGE as a modulator of gut permeability in diabetes. *Int J Mol Sci*. 2022;23(3): 1776.
 9. Serban AI, Stanca L, Geicu OI, Dinischiotu A. AGEs-induced IL-6 synthesis precedes RAGE up-regulation in HEK 293 cells: an alternative inflammatory mechanism?. *Int J Mol Sci*. 2015;16(9):20100-17.
 10. King AJ. The use of animal models in diabetes research. *Br J Pharmacol*. 2012;166(3):877-94.
 11. Vucetic M, Jensen PK, Jansen EC. Diameter variations of retinal blood vessels during and after treatment with hyperbaric oxygen. *Br J Ophthalmol*. 2004;88(6):771-5.
 12. NIH (National Institute of Health). Principles of laboratory animal care. Bethesda, MD. National Institute of Health, 1985; 1-96.
 13. Chandra S, Sheth J, Anantharaman G, Gopalakrishnan M. Ranibizumab-induced retinal reperfusion and regression of neovascularization in diabetic retinopathy: An angiographic illustration. *Am J Ophthalmol Case Rep*. 2018;9:41-44.
 14. Cen S, Hsu Y, Lin Y, Huang YC, Chen CJ, Lin WD, et al. Current concepts regarding developmental mechanisms in diabetic retinopathy in Taiwan. *Biomedicine (Taipei)*. 2016;6(2):7.
 15. Eshaq RS, Aldalati AMZ, Alexander JS, Harris NR. Diabetic retinopathy: Breaking the barrier. *Pathophysiology*. 2017;24(4):229-241.
 16. Cheung CY, Ikram MK, Sabanagayam C, Wong TY. Retinal microvasculature as a model to study the manifestations of hypertension. *Hypertension*. 2012;60:1094-103.
 17. Song P, Yu J, Chan KY, Theodoratou E, Rudan I. Prevalence, risk factors and burden of diabetic retinopathy in China: a systematic review and meta-analysis. *J Glob Health*. 2018;8(1):010803.
 18. Sasongko MB, Widyaputri F, Agni AN, Wardhana FS, Kotha S, Gupta P, et al. Prevalence of diabetic retinopathy and blindness in Indonesian adults with type 2 diabetes. *Am J Ophthalmol*. 2017;181:79–87.
 19. Croft M, Siegel RM. Beyond TNF: TNF superfamily cytokines as targets for the treatment of rheumatic diseases. *Nat Rev Rheumatol*. 2017;13(4):217-233.
 20. Liu L, Zuo Z, Lu S, Liu A, Liu X. Naringin attenuates diabetic retinopathy by inhibiting inflammation, oxidative stress and NF-κB activation *in vivo* and *in vitro*. *Iran J Basic Med Sci*. 2017;20(7):813-821.
 21. Feng Y, Gross S, Chatterjee A, Wang Y, Lin J, Hammes HP. Transcription of inflammatory cytokine TNFα is upregulated in retinal angiogenesis under hyperoxia. *Cell Physiol Biochem*. 2016;39(2):573–83.
 22. Atli H, Onalan E, Yakar B, Duzenci D, Dönder E. Predictive value of inflammatory and hematological data in diabetic and non-diabetic retinopathy. *Eur Rev Med Pharmacol Sci*. 2022;26(1):76-83.
 23. Ahuja S, Saxena S, Akduman L, Meyer CH, Kruzliak P, Khanna VK. Serum vascular endothelial growth factor is a biomolecular biomarker of severity of diabetic retinopathy. *Int J Retina Vitreous*. 2019;5:29.
 24. Simo R, Sundstrom JM, Antonetti DA. Ocular anti-VEGF therapy for diabetic retinopathy: the role of VEGF in the pathogenesis of diabetic retinopathy. *Diabetes Care*. 2014;37(4):893-9.